

Unicentric Retroperitoneal Mass: Castleman's Disease

Feyyaz Gungor , Erdinç Kamer , Ahmet Er , Ahmet Atasever , Mustafa Peşkersoy 

Department of General Surgery, İzmir Katip Çelebi University Atatürk Training and Research Hospital, İzmir, Turkey

ORCID iDs of the authors: F.G. 0000-0002-4066-6072; E.K. 0000-0002-5084-5867; A.E. 0000-0002-0101-563X; A.A. 0000-0002-7495-4160; M.P. 0000-0002-7319-2686.

Cite this article as: Gungor F, Kamer E, Er A, Atasever A, Peşkersoy M. Unicentric Retroperitoneal Mass: Castleman's Disease. *Cyprus J Med Sci* 2021; 6(1): 103-4.

Castleman's disease (CD) is a rare cause of lymphadenopathy. Its pathophysiology is unclear. It is usually asymptomatic and is incidentally detected. The treatment of unicentric CD is complete removal of the mass, and its recurrence is very rare. In this study, we present a male patient aged 36 years presenting with dyspepsia and incidentally diagnosed with unicentric CD by reviewing the data from literature.

Keywords: Castleman's disease, dyspepsia, lymphadenopathy

INTRODUCTION

Castleman's disease (CD) is a rare disease characterized by benign lymph node hyperplasia (1, 2). Although this disease may occur anywhere along the lymphatic chain, it has been reported that 7% is retroperitoneal and that 2% is pararenal (1). Unicentric CD (UCD) has a 95.3% survival rate and is usually asymptomatic (1, 3, 4). In this article, we present a male patient aged 36 years who presented with dyspepsia and was incidentally diagnosed with UCD.

CASE PRESENTATION

A male patient aged 36 years who was diagnosed with a mass in the left perirenal area was admitted to our hospital for further examination and treatment. His medical history included hypertension and coronary artery disease. He did not have significant diseases in his family history. On physical examination, no pathological finding was detected except for minimal tenderness in the left colic region. Laboratory findings were normal. On thoracoabdominal computed tomography (CT), a retrocaval, well-circumscribed, homogeneous mass lesion with a size of 60 × 50 mm compressing the vena cava (VC) at the left renal hilum level was observed, and no other pathology was detected in the scans (Figure 1). In clinical evaluation of the patient, soft tissue sarcomas, schwannoma, paraganglioma, retroperitoneal fibrosis, and CD were considered in the differential diagnosis owing to the absence of pathological findings other than isolated retroperitoneal mass. Owing to the mass proximity to the left renal vein and inferior VC inferior, a biopsy could not be taken for tissue diagnosis, and surgery was decided. Written informed consent was obtained from the patient, and elective surgery was planned. On exploration it was found that the mass was invad-

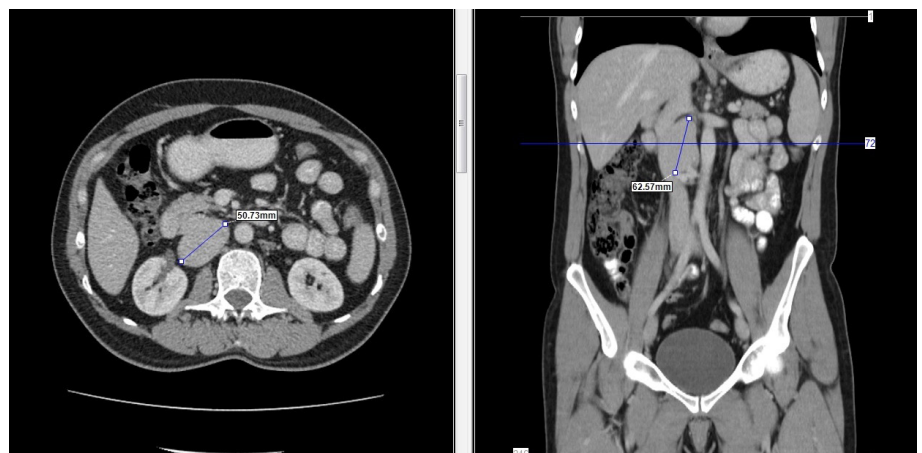

FIGURE 1. Vertical and sagittal section of computed tomography images

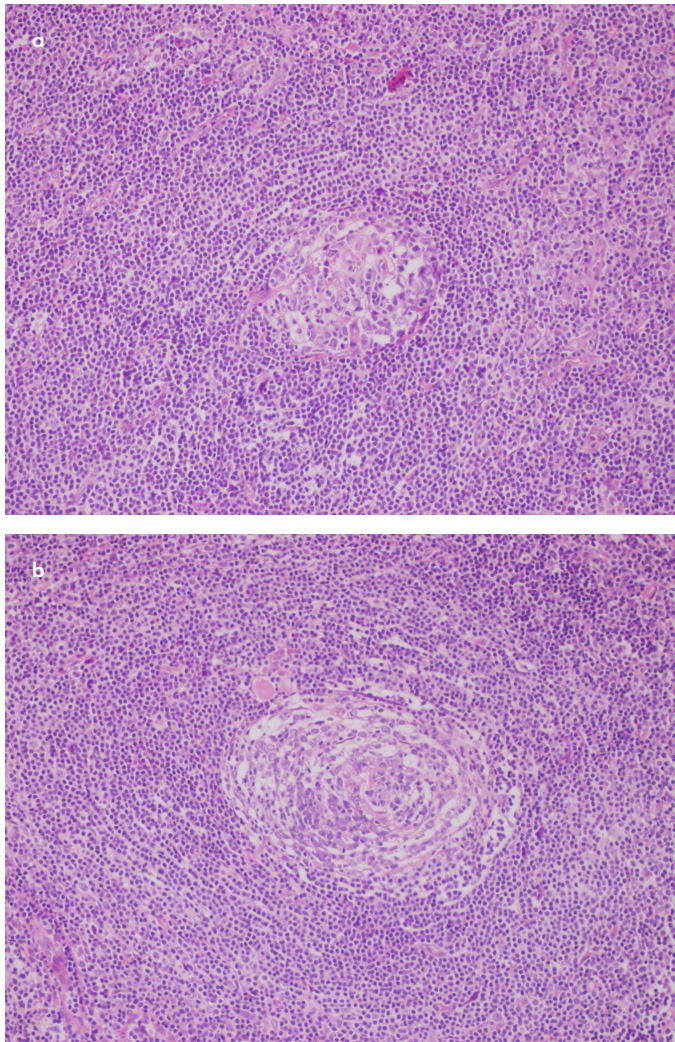


Figure 2. a, b. The microscopic image of the specimen. a) Mantle cells tend to form concentric rings. b) Expanded mantle zone and hypervascular interfollicular region

ing the left renal vein at 360° with a length of 1 cm. Perioperative frozen examination was reported to be compatible with lymphoid tissue, and partial resection was performed owing to renal vein involvement. The patient was discharged on the second postoperative day without any complications. Histopathological diagnosis was hyaline vascular-type CD (Figure 2a and b). There was no change in the size of the mass on the CT performed in the first postoperative year, and no other focus was detected.

DISCUSSION

CD is a rare cause of lymphadenopathy. The pathophysiology has not yet been clarified owing to the lack of large patient

Main Points:

- Castleman's disease (CD) is a rare cause of lymphadenopathy. Its pathophysiology is unclear. It is usually asymptomatic and is incidentally detected.
- The treatment of unicentric CD is complete removal of the mass, and its recurrence is very rare.
- CD should always be kept in mind in the differential diagnosis of retroperitoneal masses.

studies that allow controlled studies. When it was first described by Castleman in 1956, it was described as a chronic nonspecific inflammatory formation in terms of the histological pattern (5). Owing to systemic symptoms, such as fever, and lymphadenopathy and histopathological features, the etiology of the disease has been focused on viral stimulation. UCD is more benign than multicentric CD and is divided into 2 histological types (1). The hyaline vascular type, which constitutes 90% of the cases, may present with compression symptoms, but they are usually asymptomatic and are incidentally detected (4). The plasma cell type is seen in 10% of the cases, and this type is mostly detected as mesenteric and retroperitoneal (2, 4). Although there is no randomized study, complete excision of the mass is sufficient and is the gold standard method in the treatment of UCD (4). In cases where total surgical excision is not possible, partial removal of the mass has also been reported to be beneficial. Recurrence is very rare and is usually associated with incomplete resection or missed lymph nodes in the first surgery. Systemic symptoms and laboratory abnormalities, if any, are eliminated by total resection (2, 6, 7).

In conclusion, although UCD is a rare condition, it should always be kept in mind in the differential diagnosis of retroperitoneal masses.

Informed Consent: Written informed consents were obtained from the patients who participated in this study for this study and also to publish photos of the patient.

Peer-review: Externally peer-reviewed.

Author contributions: Concept - E.K.; Design - F.G.; Supervision - M.P., A.E.; Resource - A.A. Materials - E.K.; A.E.; Data Collection and/or Processing - A.E.; A.A. Analysis and/or Interpretation - F.G.; Literature Search - F.G., E.K.; Writing - E.K., F.G.; Critical Reviews - M.P., A.E.

Conflict of Interest: Authors have no conflicts of interest to declare.

Financial Disclosure: The authors declared that this study has received no financial support.

REFERENCES

1. Soumerai JD, Sohani AR, Abramson JS. Diagnosis and management of Castleman disease. *Cancer Control* 2014; 21(4): 266-78. [\[Crossref\]](#)
2. Keller AR, Hochholzer L, Castleman B. Hyaline-vascular and plasma-cell types of giant lymph node hyperplasia of the mediastinum and other locations. *Cancer* 1972; 29(3): 670-83. [\[Crossref\]](#)
3. Waterston A, Bower M. Fifty years of multicentric Castleman's disease. *Acta Oncol* 2004; 43(8): 698-704. [\[Crossref\]](#)
4. Talat N, Belgaumkar AP, Schulte KM. Surgery in Castleman's disease: a systematic review of 404 published cases. *Ann Surg* 2012; 255(4): 677-84. [\[Crossref\]](#)
5. Castleman B, Iverson L, Menendez VP. Localized mediastinal lymphnode hyperplasia resembling thymoma. *Cancer* 1956; 9(4): 822-30. [\[Crossref\]](#)
6. Dupin N, Diss TL, Kellam P, Tulliez M, Du MQ, Sicard D, et al. HHV-8 is associated with a plasmablastic variant of Castleman disease that is linked to HHV-8-positive plasmablastic lymphoma. *Blood* 2000; 95(4): 1406-12. [\[Crossref\]](#)
7. Chronowski GM, Ha CS, Wilder RB, Cabanillas F, Manning J, Cox JD. Treatment of unicentric and multicentric Castleman disease and the role of radiotherapy. *Cancer* 2001; 92(3): 670-6. [\[Crossref\]](#)