

A Case of Thrombus Formation in a Patient with Preserved Left Ventricle Ejection Fraction and Development of Peripheral Embolization

Zehra Erkal, Nermin Bayar, Şakir Arslan

Department of Cardiology, Health Sciences University, Antalya Training and Research Hospital, Antalya, Turkey

Cite this article as: Erkal Z, Bayar N, Arslan Ş. A case of thrombus formation in a patient with preserved left ventricle ejection fraction and development of peripheral embolization. *Cyprus J Med Sci* 2017; 2: 38-9

Echocardiography is a substantial imaging modality for evaluating intracardiac masses. Thrombi and primary or metastatic cardiac tumors should be considered in the differential diagnosis of left ventricle (LV) masses. Thrombus formation in the LV generally occurs because of diseases that cause LV systolic dysfunction. Some cases have been reported to be related to thrombus formation in patients with a normal LV ejection fraction. Physicians should consider that a thrombus might develop in patients with a normal ejection fraction.

Keywords: Thrombus, embolization, echocardiography

INTRODUCTION

Thrombus formation in the left ventricle (LV) generally occurs because of diseases that cause LV systolic dysfunction such as dilated cardiomyopathy, myocardial infarction, and aneurysm. Here we present the case of a patient with an LV thrombus and peripheral embolization and who had a normal LV systolic function.

CASE PRESENTATION

A 63-year-old male patient with severe pain in the left leg was admitted to the emergency department. He underwent embolectomy of the right femoral artery 2 weeks ago at another hospital. The patient's physical examination was quite normal, except for the absence of left popliteal and distal pulses. His blood pressure was 113/67 mmHg, with a pulse rate of 67 beats/min. Electrocardiogram revealed a normal sinus rhythm. The ejection fraction of LV was 65%, and a mobile, pedunculated heterogeneous mass originating from the interventricular septum and measuring 1.3x1.1 cm in diameter was observed on echocardiography (Figure 1). It was primarily considered to be a myxoma rather than a thrombus. Peripheral angiography was performed, and acute 100% obstruction was detected at the left femoral artery on an angiogram. Therefore, emergency left femoral embolectomy was performed by cardiovascular surgeons. Histopathology of the embolectomy specimen was relevant with a thrombus. Thus, echocardiography was repeated, and a 4-mm-sized residual mass was detected 3 days after the surgery (Figure 2). Factor V Leiden and prothrombin 20210 mutation tests were negative, and protein C and S and antithrombin 3 levels and eosinophil counts were all normal. Moreover, tests for Antinuclear anticore level and lupus anticoagulants were negative. The patient was anticoagulated with warfarin, with a target INR of 2-3. The patient's consent was obtained.

DISCUSSION

Echocardiography is a substantial imaging modality for evaluating intracardiac masses. Thrombi and primary or metastatic cardiac tumors should be considered in the differential diagnosis of LV masses (1-6). Myxoma was primarily considered to be the diagnosis because of a mobile, pedunculated mass in a normal functioning LV, although, with a low probability, our differential diagnosis included a thrombus (7).

Protein C and S deficiency, antiphospholipid syndrome, myeloproliferative disorders, idiopathic hypereosinophilic syndrome, pheochromocytoma, and Takatsubo cardiomyopathy were reported to be related with thrombus formation in patients with a normal LV ejection fraction (8-10).

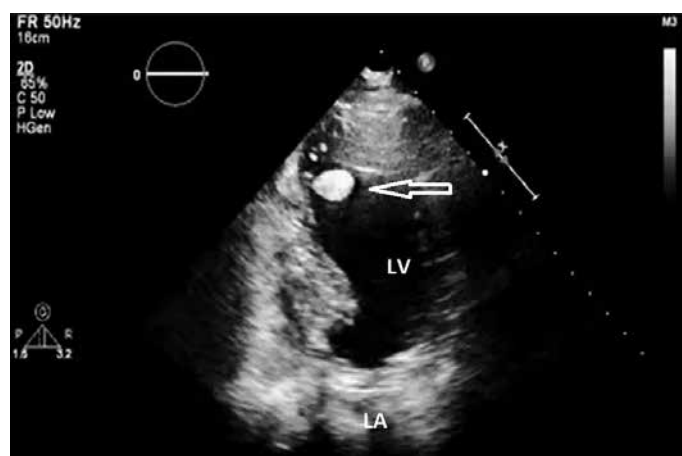

FIGURE 1. Thrombus image clinging to the left ventricle

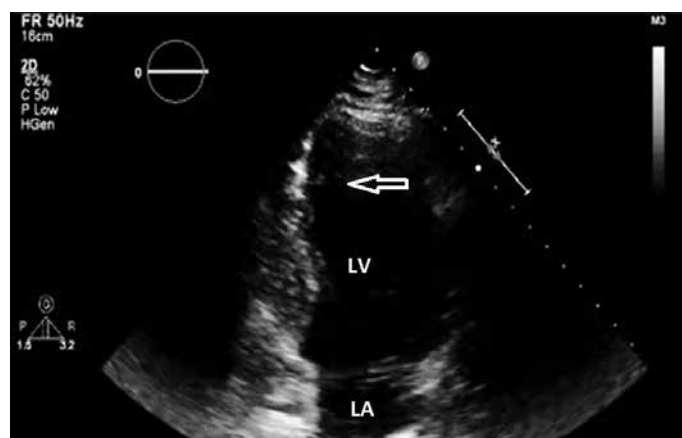


FIGURE 2. After embolization residual thrombus in the septum

Clinical and laboratory findings of our case were all normal. LV thrombus formation and peripheral embolization are extremely rare in patients with a normal ejection fraction and without any etiologic cause, as in our case (7).

Physicians should be careful regarding LV thrombus or mass formation in patients with a history of systemic embolus. Furthermore, it should be considered that a thrombus might develop in patients with a normal ejection fraction.

Informed Consent: Informed consent was obtained from the patient who participated in this study.

Peer-review: Externally peer-reviewed.

Author contributions: Concept - Z.E.; Design - Z.E., N.B.; Supervision - N.B., Ş.A.; Resource - N.B.; Materials - Z.E.; Data Collection and/or Processing - Z.E., Ş.A.; Analysis and/or Interpretation - Ş.A.; Literature Search - Z.E., N.B.; Writing - Z.E., N.B.; Critical Reviews - Ş.A.

Conflict of Interest: No conflict of interest was declared by the authors.

Financial Disclosure: The authors declared that this study has received no financial support.

REFERENCES

1. Levisman JA, MacAlpin RN, Arbasi AS, Ellis N, Eber LM. Echocardiographic diagnosis of a mobile, pedunculated tumor in the left ventricular cavity. *Am J Cardiol* 1975; 36: 957-9. [\[CrossRef\]](#)
2. Ports TA, Cogan J, Schiller NB, Rapaport E. Echocardiographic of left ventricular masses. *Circulation* 1978; 58: 528-36. [\[CrossRef\]](#)
3. Schamaier AH, Denenberg B. Left ventricular thrombus with normal left ventricular function and hyperaggregable plates in a patient with polycystic disease of multiple organs. *Am J Med Sci* 1984; 288: 233-7.
4. DeGroat TS, Parameswaran R, Popper PM, Kotler MN. Left ventricular thrombi in association with normal left ventricular wall motion in patients with malignancy. *Am J Cardiol* 1985; 56: 827-8. [\[CrossRef\]](#)
5. Asinger RW, Mikell FL, Sharma B, Hodges M. Observations on detecting left ventricular thrombus with two dimensional echocardiography: emphasis on avoidance of false positive diagnoses. *Am J Cardiol* 1981; 47: 145-56. [\[CrossRef\]](#)
6. Keren A, Takamoto T, Harrison DC, Popp RL. Left ventricular apical masses: Noninvasive differentiation of rare from common ones. *Am J Cardiol* 1985; 56: 697-9. [\[CrossRef\]](#)
7. Eren NK, Emren SV, Duygu H, Kocabas U. Left ventricular thrombus formation in a patient with normal ejection fraction. *Turk Kardiyol Dern Ars* 2013; 41: 625-8. [\[CrossRef\]](#)
8. Verma AK, Alam M, Romsan HS, Brymer J, Keith F. Systemic embolization from thrombus in normal left ventricles. *Chest* 1988; 93: 441-2. [\[CrossRef\]](#)
9. Matitieu A, Tabachnik E, Sthoeger D, Birk E. Thrombus in the left ventricle of a child with systemic emboli: an usual presentation of hereditary protein C deficiency. *Pediatrics* 2001; 107: 421-2. [\[CrossRef\]](#)
10. Kawamoto J, Ishibashi K, Shibukawa T, Izutani H. Left ventricular thrombus with a normal heart. *Gen Thorac Cardiovasc Surg* 2007; 55: 322-4. [\[CrossRef\]](#)