

Early-Term Perforation after Mitral Valve Repair And Significance of Three-Dimensional Echocardiography

Zehra Erkal, Nermin Bayar, Çağın Mustafa Üreyen, Şakir Arslan

Clinic of Cardiology, Antalya Training and Research Hospital, Antalya, Turkey

Cite this article as: Erkal Z, Bayar N, Üreyen ÇM, Arslan Ş. Early-Term Perforation after Mitral Valve Repair And Significance of Three-Dimensional Echocardiography. *Cyprus J Med Sci* 2017; 2: 79-80.

Diagnosis of complications following valvular surgery is established by echocardiographic examination, principally with transesophageal echocardiography and three-dimensional (3D) echocardiography. Valvular perforation is very rarely seen and is particularly related to infective endocarditis. We present the case of a patient with valvular perforation that occurred in the early postoperative period and was diagnosed using 3D echocardiography.

Keywords: Surgery, perforation, echocardiography

INTRODUCTION

There are early- and late-term complications following valvular surgery. Valvular perforation is very rarely seen and is particularly related to infective endocarditis; it may occasionally be related to iatrogenic causes. Diagnosis is established using echocardiographic examination, principally with transesophageal echocardiography (TEE) and three-dimensional (3D) echocardiography.

CASE PRESENTATION

A 60-year-old male patient who underwent mitral valve repair 2 months ago was admitted to the internal medicine ward for the investigation of the etiology of hemolytic anemia. The patient's physical examination and electrocardiogram results were unremarkable. Transthoracic echocardiography (TTE) and 2D-3D TEE were performed, and severe mitral regurgitation was detected; his blood pressure was 124/68 mmHg. Severe mitral regurgitation was caused by the dehiscence of the mitral ring and perforation of the mitral valve concomitantly (Figure 1, 2). The patient did not have high fever in the 2 months postoperatively, and his white blood count, sedimentation rate, and C-reactive protein level were in a normal range. Reoperation was recommended, and no complications developed after reoperation. We report this case because mitral valve perforation is a very rare complication in the early postoperative period without the presence of infective endocarditis and to emphasize the significance of 3D echocardiography. The patient was confirmed. Informed consent was taken from the patient.

DISCUSSION

Echocardiographic examination is very important in the follow-up of patients who undergo valvular surgery, particularly when a new murmur is noted. Diagnosis of valvular perforation should be kept in mind in the differential diagnosis of eccentric valvular regurgitation (1).

It is difficult to distinguish whether regurgitation is due to valvular perforation. Structural valvular degeneration should be excluded using TEE and particularly 3D echocardiography when hemolysis or a new murmur develops after valvular surgery (2).

Transesophageal echocardiography is an excellent diagnostic modality to reveal detailed anatomic localization of perforation as it provides exact details of mitral valve anatomy because of perfect visualization. Perforation could be confused with chordal rupture, vegetation, or mass; therefore, TEE and particularly 3D echocardiography is very effective in the differential diagnosis (3).

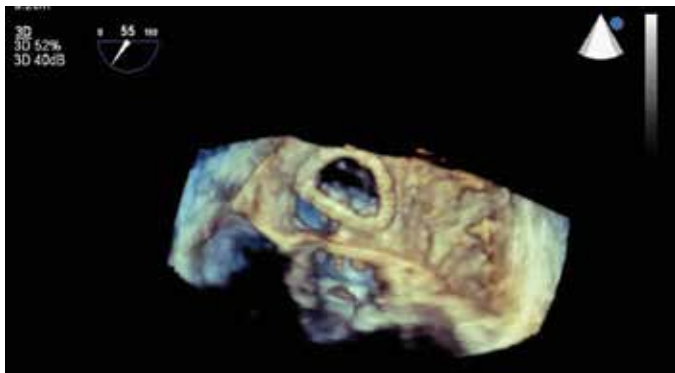


FIGURE 1. Two-dimensional transesophageal view of mitral valve perforation

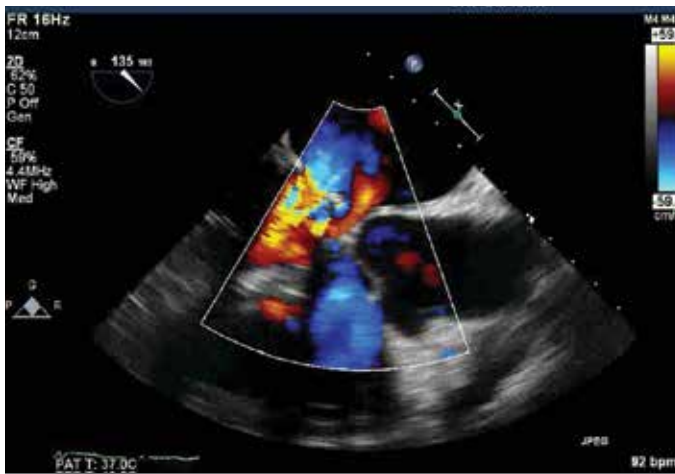

FIGURE 2. 3D transesophageal view of mitral valve perforation

CONCLUSION

Valvular perforation should be kept in mind as a rare complication after valvular surgery. 3D echocardiography should be performed for diagnosis when feasible.

Informed Consent: Written informed consent was obtained from the patient who participated in this study.

Peer-review: Externally peer-reviewed.

Author Contributions: Concept - Z.E.; Design - Z.E., N.B.; Supervision - N.B., Ş.A.; Resource - Ç.Ü.; Materials - Z.E., Ç.Ü.; Data Collection and/or Processing - Z.E., N.B.; Analysis and/or Interpretation - Ş.A.; Literature Search - N.B.Ç.Ü.; Critical Reviews - Z.E., Ş.A.

Conflict of Interest: No conflict of interest was declared by the authors.

Financial Disclosure: The authors declared that this study has received no financial support.

REFERENCES

1. Takano T, Seto T, Asaka S, Terasaki T, Ohashi N, Fukui D, et al. Structural valve deterioration of porcine bioprosthesis soon after mitral valve repair and replacement. *Ann Thorac Cardiovasc Surg* 2014; 20: 717-9. [\[CrossRef\]](#)
2. Al Yamani MI, Frapier MJ, Battistella PD, Albat B. Right coronary cusp perforation after mitral valve replacement. *Interact Cardiovasc Thorac Surg* 2013; 16: 387-8. [\[CrossRef\]](#)
3. Holmes A, Hung T, Human DG, Campbell AI. *Kingella kingae* endocarditis: A rare case of mitral valve perforation. *Ann. Pediatr Cardiol* 2011; 4: 210-2. [\[CrossRef\]](#)