

Spontaneous Ileoileal Intussusception in a Young Adult

Erdinc Kamer¹ , Serkan Karaisli¹ , Can Dundar² , Mustafa Peskersoy¹ 

¹Department of General Surgery, İzmir Katip Çelebi University Atatürk Training and Research Hospital, İzmir, Turkey

²Department of Radiology, İzmir Katip Çelebi University Atatürk Training and Research Hospital, İzmir, Turkey

ORCID IDs of the Authors: E.K. 0000-0002-5084-5867; S.K. 0000-0001-8876-0191; C.D. 0000-0003-4189-5771; M.P. 0000-0002-7319-2686

Cite this article as: Kamer E, Karaisli S, Dundar C, Peskersoy M. Spontaneous Ileoileal Intussusception in a Young Adult. *Cyprus J Med Sci* 2018; 3: 124-6.

Dear Editor,

An 18-years-old woman was admitted to emergency service with severe abdominal pain and nausea for the last two days. She denied any history of abdominal surgery or familial disease. Abdominal distension and rigidity were found and a 5 cm diameter mass was palpated during abdominal examination. Vital signs were insignificant. Leucocyte count was 18590/mm³. The abdominal X-ray revealed dilated bowel loops. Abdominal ultrasonography reported the case as suspicious of intussusception of ileum. Contrast-enhanced abdominal computed tomography (CT) revealed dilated small bowel loops due to ileoileal intussusceptions (target sign) and free fluid in the Douglas pouch (Figure 1 a, b).

The patient was taken to operating room. Ischemic bowel loops were seen (Figure 2-3). The pathologic intestinal segment was removed, and the small bowel was anastomosed by a linear stapler. The postoperative duration was uneventful, and she was discharged five days after surgery. Pathological examination revealed a 45 centimeters-long intestine with intussusception without any luminal lesion. She had remained well during 22-month follow-up. Written informed consent was obtained from the patient who participated in this study.

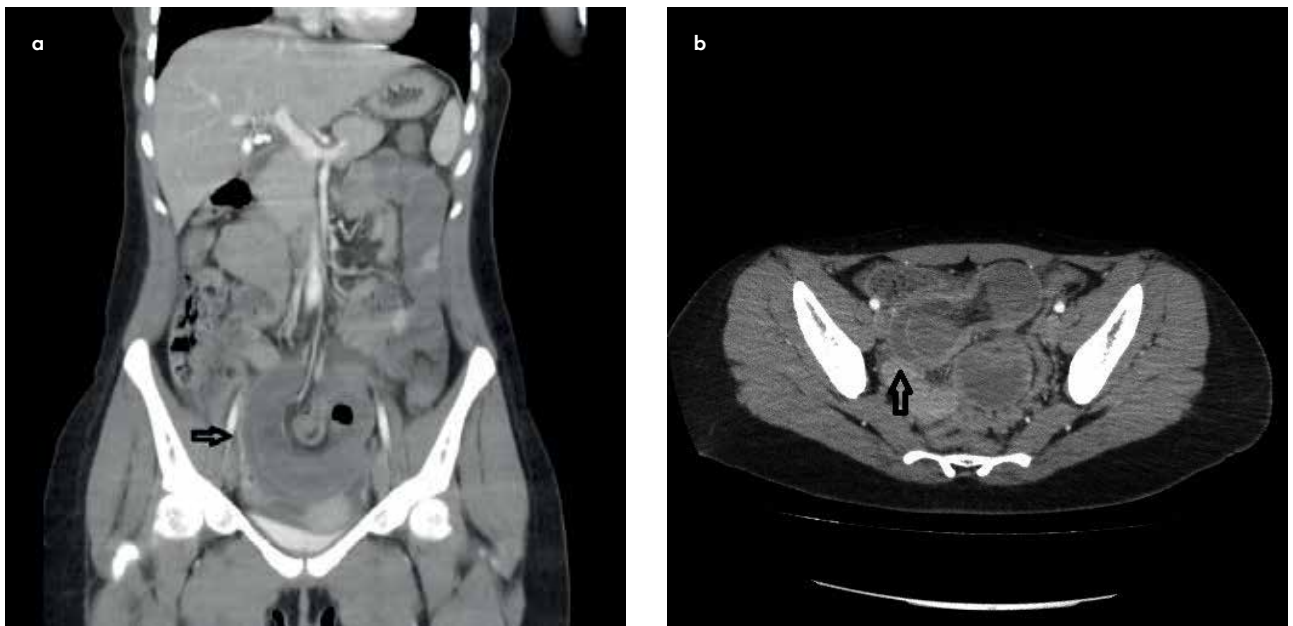

FIGURE 1. a, b. Arrow: Intussuscepted ileal loops in coronal (a) and axial (b) computed tomography images.

This study was presented as a poster at the 11th Turkish Congress of Trauma & Emergency Surgery, April 5-9, 2017, Antalya, Turkey.

Corresponding Author: Serkan Karaisli

E-mail: skaraisli@hotmail.com

Received: 04.03.2018

Accepted: 05.06.2018

©Copyright 2018 by Cyprus Turkish Medical Association - Available online at www.cypriusjmedsci.com

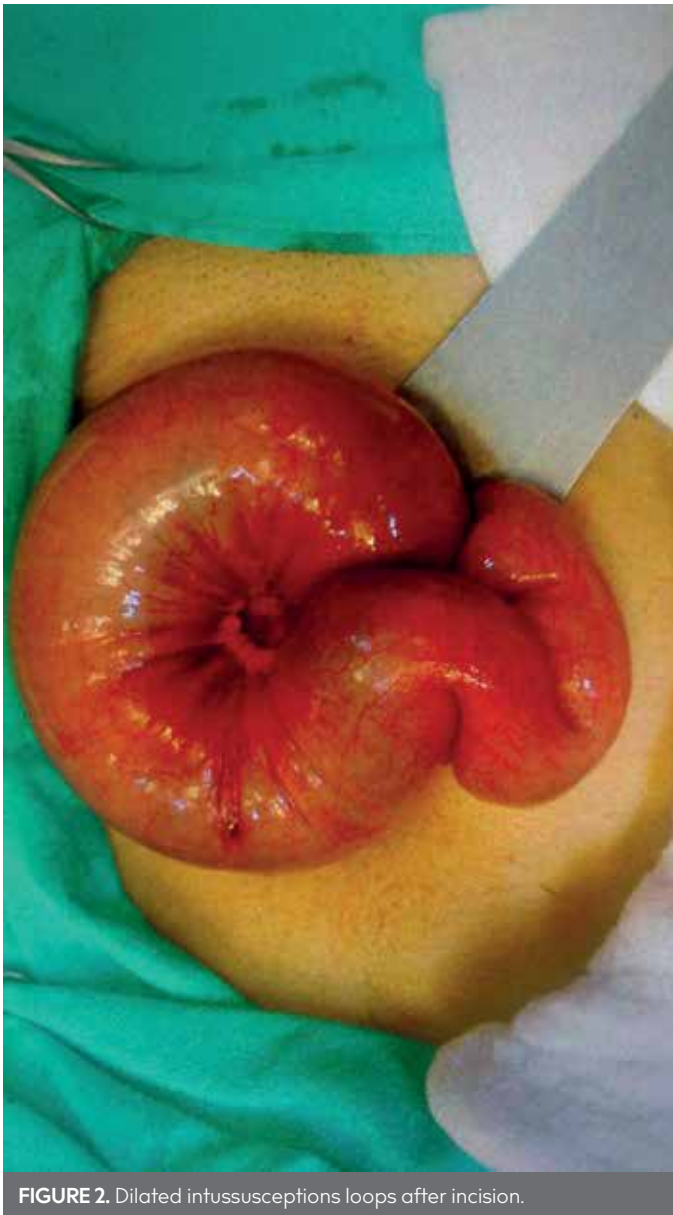


FIGURE 2. Dilated intussusceptions loops after incision.

Intussusception is telescoping of a proximal segment of the gastrointestinal tract into an adjacent distal segment. It happens frequently during childhood, whereas adult intussusceptions constitute only 5% of all intussusception cases. Benign or malignant tumors are causes for more than 90% of intestinal obstruction cases in adults (1). Intussusception is categorized into subgroups such as enteroenteric, colocolic, ileocolic, or ileocecal according to the affected bowel segments (2).

Abdominal mass, rectal bleeding, and pain is a typical triad of pediatric intussusception; however, it is mostly subacute (24%) or chronic (51%) in adults (3). The patient we present had abdominal pain and a palpable mass, which was similar to pediatric patients.

Preoperative diagnosis is difficult. Ultrasound is the preferred imaging method for pediatric intussusceptions, whereas it is not used for diagnoses in most adult cases due to bowel obstruction-related intestinal gas (2). Although approximately 50% of patients are diagnosed during surgery, CT has a diagnostic accuracy rate of up to 100% in adult intussusceptions (4).

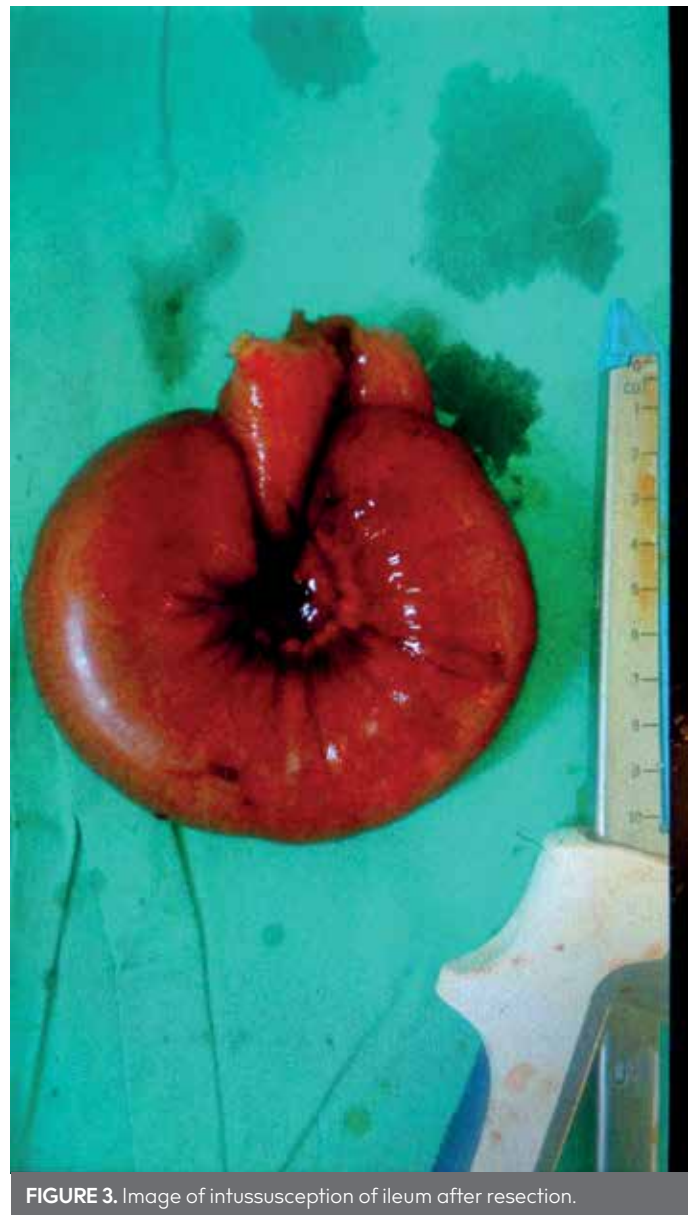

FIGURE 3. Image of intussusception of ileum after resection.

On CT images, sausage-shaped mass on the longitudinal axis and target sign on the transverse axis describe intussusception. Mesenteric vessels located in the bowel lumen may also help to establish a final diagnosis (4).

Although majority of childhood intussusceptions may be treated conservatively, surgery for adult intussusception was reported as the most effective treatment. Resection without reduction is the gold standard treatment in adults because intussusceptions in adults are mostly related to malignancy and reduction may increase the risk of bowel perforation (2, 4).

As a result, bowel intussusceptions in adulthood are rare and mostly include a malignant base. Preoperative diagnosis is mostly delayed because most patients have insignificant symptoms. CT is important for prompt diagnosis. Urgent surgery should be considered in the case of acute abdomen.

Informed Consent: Written informed consent was obtained from the patient who participated in this study.

Peer-review: Externally peer-reviewed.

Author contributions: Concept - E.K., S.K.; Design - S.K., M.P.; Supervision - E.K., C.D.; Fundings - E.K., C.D.; Materials - S.K., C.D.; Data Collection and/or Processing - E.K., M.P.; Analysis and/or Interpretation - E.K., S.K.; Literature Search - S.K.; Writing - E.K., S.K.; Critical Reviews - M.P.

Conflict of Interest: The authors have no conflicts of interest to declare.

Financial Disclosure: The authors declared that this study has received no financial support.

Acknowledgements: We thank all general surgery staff for their contribution.

REFERENCES

1. Patrizi G, Di Rocco G, Giannotti D, Casella G, Casella Mariolo JR, Bernieri MG, et al. Double ileo-ceco-colic invagination due to right colon carcinoma: clinical presentation and management. *Eur Rev Med Pharmacol Sci* 2013; 17: 2267-2269.
2. Lu T, Chng YM. Adult intussusception. *Perm J* 2015; 19: 79-81.
3. Gonzalez-Hernandez J, Garcia F. Cecal adenocarcinoma presenting as colonic intussusception in adulthood. *Proc (Bayl Univ Med Cent)* 2015; 28: 180-182. [\[CrossRef\]](#)
4. Lianos G, Xeropotamos N, Bali C, Baltoggiannis G, Ignatiadou E. *G Chir* 2013; 34: 280-283.